

# Human Ocular Thelaziasis: A Case Report from Indonesia

*by* Andi Muhammad Ichsan

---

**Submission date:** 21-Jun-2022 09:34PM (UTC+0700)

**Submission ID:** 1860782334

**File name:** 22.Human\_Ocular\_Thelaziasis\_A\_Case.pdf (588.14K)

**Word count:** 3296

**Character count:** 17555

Case Report

## Human Ocular Thelaziasis: A Case Report from Indonesia

Liem Meysie Kristi Harlimton<sup>a</sup> Sitti Wahyuni<sup>b</sup> Alif Reza<sup>a</sup>  
Junaedi Sirajuddin<sup>a</sup> Hasnah B. Eka<sup>a</sup> Itzar Chaidir Islam<sup>a</sup>  
Andi Muhammad Ichsan<sup>a</sup>

<sup>a</sup>Department of Ophthalmology, Faculty of Medicine, Hasanuddin University, Makassar, Indonesia; <sup>b</sup>Department of Parasitology, Faculty of Medicine, Hasanuddin University, Makassar, Indonesia

### Keywords

Thelaziasis · *Thelazia callipaeda* · Human ocular · Indonesia

### Abstract

Thelaziasis is a parasitic disease caused by a nematode of genus *Thelazia*, which is rare in the world, including Indonesia. The definitive hosts for *Thelazia* are canids, felids, mustelids, and other mammals, while the vector is drosophila flies. Consequently, this study reported an uncommon occurrence of human ocular thelaziasis in Indonesia. Based on the patient's complaints and physical examination, we found a living worm that move actively in the anterior chamber; then documentation is carried out both during the examination at the polyclinic and in the operating room. The surgery was performed using topical anaesthesia, clear corneal incision, and removing worm through the main port. Morphological examination from the parasitology laboratory showed that the worm was *Thelazia callipaeda* species. Following this intervention, the patient was given an oral anti-helminthics drug, topical and oral antibiotics, topical steroid, and surgical treatment. There was no recurrence or appearance of any other symptoms reported in 2 months of follow-up.

### Introduction

The epidemiology of parasitic ocular diseases can be explained by the causative organism's habitat as well as the patient's habits and health status. Furthermore, an ocular examination may provide information about the underlying infection, and knowledge of the possibilities

Correspondence to:  
Andi Muhammad Ichsan, [am\\_ichsan@med.unhas.ac.id](mailto:am_ichsan@med.unhas.ac.id)

of travel-related pathology may explain the disease symptoms [1]. Thelaziasis is a parasitic condition caused by a nematode of the genus *Thelazia*, which infects the eyes of wild and domestic animals. The species associated with this disease include *Thelazia californiensis* and *Thelazia gulosa*, which have been reported in the USA, along with *Thelazia callipaeda*, which is common in Asia and affects humans [2]. Meanwhile, canids of domestic and wild origins are concerned as the primary definitive hosts for *Thelazia callipaeda*, though infections in mustelids, lagomorphs, and felids have been identified [3]. *Thelazia californiensis* infections have been detected in several mammals, mostly domestic and wild canids, as well as cervids, jackrabbits (*Lepus californicus*), bears, sheep, and felids. The intermediate vectors or hosts for these parasites are psychophilid flies, which consume lacrimal secretions (lacrimophagous). *Fannia* spp., including *Fannia benjamini* (canyon fly) and *F. canicularis* (lesser house fly), are the hosts of *T. californiensis*, while *Phortica variegata* and *Phortica okadai* are the primary intermediate vectors of *T. callipaeda*. The vectors feed on the conjunctival secretions of infected animals, thereby ingesting the parasite's first-stage larvae, which are produced from the eggshell and covered in sock-like membranes [4]. Subsequently, the parasites mature into the third larval or infective stage in 2–3 weeks while in the vector before migrating to the fly's trunk for transmission to a new host. These flies, which are active during the daytime, land on the eye and release infective larvae onto the conjunctiva while feeding on lacrimal fluid [5].

The first case of human thelaziasis was discovered in Asian countries, owing to the disease's spread in the former Soviet Union and Far East countries, including Korea, Nepal, China, Thailand, India, and Europe [3, 6–10]. This contrasts with Southeast Asian countries, such as Thailand, Myanmar, Vietnam, and Indonesia, where only a small number of ocular thelaziasis cases have been reported [11, 12].

This work has been reported in line with the improved SCARE checklist (online suppl. Material 1; for all online suppl. material, see [www.karger.com/doi/10.1159/000525117](http://www.karger.com/doi/10.1159/000525117)). The SCARE guidelines were published in 2016 and modified in 2018 to provide a structure for surgical reports [13].

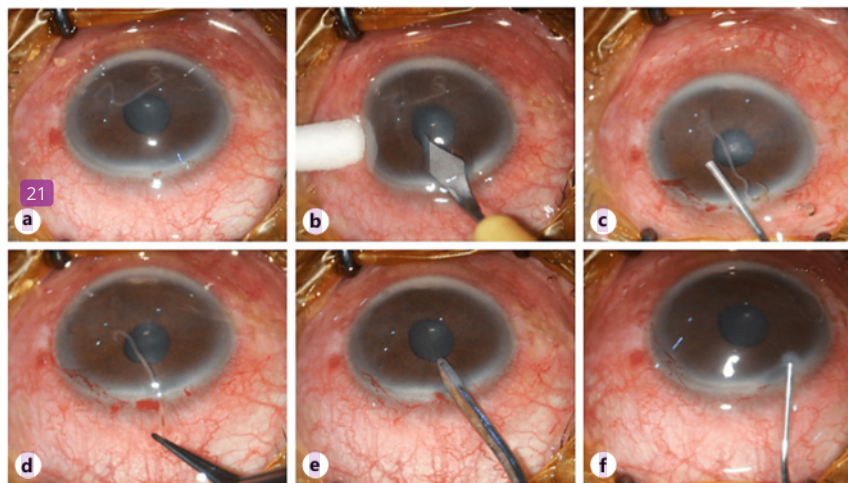
## 28

### Case Presentation

A 49-year-old man with the complaint of a moving worm in the left eye was referred to Hasanuddin University Hospital. The initial symptom was blurred vision, followed by redness and an itchy feeling in the left eye that began about 2 weeks later. A history of trauma, systemic disease, and previous ocular symptoms were denied. According to the information obtained, the patient was a farmer who resided in a district about 500 km from the capital city, where humans and animals coexisted, and no similar history had been reported in his neighbourhood.

Subsequently, the visual acuity of the right and left eyes were 20/20 and 1/60, while the intraocular pressure measured with noncontact tonometry obtained 11 and 10 mm Hg, respectively. The slit-lamp examination revealed conjunctival hyperaemia, corneal and palpebral oedema, minimal lens opacification at the anterior capsule, and a living worm in the anterior chamber of the left eye. In addition, the assessment indicated that the right eye was normal, the funduscopic examination showed a normal posterior segment, and routine investigations, including chest X-rays and blood tests, were conducted to rule out systemic disorders.

The surgery was performed under topical and intracameral anaesthesia of lidocaine; the worm was then extracted from the patient's eye via a clear corneal incision made at the superior with a keratome blade. The injection of ophthalmic viscosurgery devices roused positive pressure in the anterior chamber resulting the worm moved out through the main incision as shown in Figure 1. The worm transferred immediately into the tissue container



**Fig. 1.** **a** Surgical removal of the worm (arrow) from the anterior chamber. **b** A clear corneal incision was made using keratome. **c** A small amount of lidocaine and viscoelastic material were inserted into the anterior chamber. **d** The worm was extracted using micro-surgery tweezers. **e** Aspiration and irrigation to remove the OVD. **f** Device was extracted from the anterior chamber.


was then identified in the Parasitology Laboratory of the Faculty of Medicine of Hasanuddin University and the University of Indonesia. This involved submerging the organism in a formalin solution, resulting in the appearance of a creamy-white-coloured worm measuring 13 mm long and 0.3 mm wide with both ends tapered. The species was identified as *Thelazia callipaeda* based on the morphology of the organism, particularly the width of the smooth and nonprominent cuticle striations, and the posterior ventral curving indicated that the nematode was male (Fig. 2).

Following this intervention, the patient was given levamisole 250 mg single dose, natrium diclofenac 50 mg b.i.d., ciprofloxacin 500 mg b.i.d., topical antibiotic, and topical steroid. The post-operative inflammation subsided in 1 week, remaining a minor lesion on the corneal endothelium and minimal lens opacity at the anterior capsule. During the follow-up a month after the surgery, the visual acuity of the left eye slightly improved to 3/60. There was no recurrence or appearance of any other symptoms reported in 2 months of follow-up.

## Discussion/Conclusion

Ocular parasitosis in human is a prevalent disease in certain areas, which depends on the habitat of the causative organism, vector of transmission, the host's habits, and environmental factors. Meanwhile, thelaziasis is caused by nematodes of the genus *Thelazia* (known as "eyeworms"), which parasitize the orbital cavity and related structures in birds and mammals, including humans, rodents, dogs, monkeys, cattle, deer, cats, pigs, foxes, horses, and camels. *Thelazia* parasites feed on the tears or ocular secretions of their host and are common in regions with poor hygiene and sanitation where humans live near animals [14].

Thelaziasis report is still rare especially in Asia; throughout our library search, this present case is the second ocular thelaziasis occurrence in the country where the worm resided in the anterior chamber, while Indonesia's first case occurred in North Sumatra



**Fig. 2.** **a** The anterior part of the nematode has a tapered end, though the lips and buccal cavity were not visible. Cuticle stylization appeared smooth with narrow spaces. **b** Posterior area of the adult male showing spicules (arrows), and the anal canal appears at the end of the tail. The curved posterior sections and long spicules are characteristic of adult male nematodes. **c** Mid-section of the nematode with intestinal tube and transversally striated smooth cuticle. **d** The appearance of adjacent stria in the cuticle is characteristic of *Thelazia callipaeda*.

reported in 1989 in a 10-month-old child [15]. In this study, the patient was living and working as a farmer in a rural area and had a cat in his house, all of which may be related to this pathological finding. Several studies suggested a relationship between human ocular thelaziasis and rural settings, improper personal hygiene, low socio-economic status, and rearing livestock or parasitized animals, such as sheep, dogs, pigs, and cats, in the same environment where humans reside [16–18].

*Thelazia* is a member of nematode family and has a length of 7–20 mm. The adult worms are creamy-white and thread-like with transversely striated cuticles. Their open mouth is hexagonally shaped, with a well-developed buccal cavity and a slightly short esophagus. Generally, male *Thelazia* species have lengths ranging between 5 and 12 mm and widths 0.3–0.4 mm, while the female is slightly above 10 mm to nearly 20 mm long with widths between 0.4 and 0.5 mm. Male nematodes can be distinguished macroscopically from females

by the indentation on the posterior area as they possess 6–10 pairs of pre-cloacal papillae and 3–5 pairs of post-cloacal papillae. Meanwhile, the female parasite is recognized by a genital opening known as the vulva, which has a slight flap and is located in the anterior region near the esophageal-intestinal junction. The female's posterior end is rounded and blunt, with a pair of lateral papillae under the surface, and the anal canal is close to the tail tip. Therefore, the number of male pre- and post-cloacal papillae, as well as the position of the female vulva, is used for sex differentiation of *Thelazia* species. In this study, the parasite species were identified as *Thelazia callipaeda* based on the morphology of the worm [11, 19, 20].

*Thelazia* worms parasitize the orbital cavity and related structures of the eye, such as the conjunctival sac, nictitating membrane, as well as nasal and lacrimal ducts. Although a few cases of intraocular thelaziasis have been reported, this case discovered a worm in the anterior chamber, and similar cases have been reported in Pakistan and Nepal [14, 21, 22]. However, the process of the worm's entry into the anterior chamber is still unidentified as the mouth of *T. callipaeda* lacks hooks or sharp spines, making tissue penetration unlikely. Although the route of entry into the eyes is still undetermined, some studies suggested the skin or the ingestion of untreated drinking water containing the larvae or embryonated eggs as a plausible means [23]. Despite various investigations, the ability of the larvae to penetrate human skin and travel along the bloodstream or the larvae and embryonated eggs to survive in the human digestive tract is still unexplained. However, previous studies proved that *Thelazia* parasites are transmitted by intermediate hosts that land on the eye region and discharge larvae into the conjunctiva [9, 24].

Worm extraction is the definitive treatment for alleviating the symptoms of infestation. Furthermore, the effectiveness of levamisole and ivermectin for similar infestations in Asia and Europe has been reported [6, 25]. Studies also recommend irrigation with lugol's iodine or 2–3% boric acid after removing the worms or when the parasites are suspected to be in the lacrimal tract [26]. For this patient, 5 mg/kg BW of levamisole was used to eradicate the parasite after the thelaziasis diagnosis was confirmed by parasitologist. During 2 months observation, the patient did not complain of recurrence and any other related symptoms.

As a conclusion, this case of ocular thelaziasis caused by *Thelazia callipaeda*, a rare form of parasitosis in Indonesia, was discovered in South Sulawesi. The definitive treatments for this condition are worm extraction and the administration of an anti-helminthic drug. Consequently, this case highlights the importance of parasite identification based on clinical presentation and parasitologic confirmation.

## Acknowledgments

The author would like to thank Professor Agnes Kurniawan from the Department of Parasitology, University of Indonesia, for the intensive discussion on parasite morphology. We also appreciate the team of nurses and staff of Hasanuddin University Hospital for their kind support.

## Statement of Ethics

All procedures performed in this study were in accordance with the ethical standards of the institutional and national research committee with the 1964 Helsinki Declaration standards. The study was reviewed and approved by the Ethics Committee of Medical Research,

Faculty of Medicine, Hasanuddin University (No. 108/UN.4.6.4.5.31/PP36/2022). Written informed consent was obtained from the patient for all medical examinations, treatments, and also publication of this case report including any accompanying images.

## Conflict of Interest Statement

The authors state that there was no conflict of interest in documenting this study.

## Funding Sources

This manuscript did not receive any funding.

## Author Contributions

Liem Meysie Kristi Harlinton: conception and design of the work, caring for the patient, performing follow-up after surgery, analysis, interpretation of data, and drafting the work. Sitti Wahyuni: parasite identification and laboratory analysis. Alif Reza: performing the surgery. Junaedi Sirajuddin and Hasnah B. Eka: revising the work critically for important intellectual content. Itzar Chaidir Islam: project administrator and drafting and revising the work critically for important intellectual content. Andi Muhammad Ichsan: conception or design of the work, perform surgery, and revising the work critically for important intellectual content.

## Data Availability Statement

All data that support the findings of this study are included in this article. Further enquiries can be directed to the corresponding author.

## References

- 1 Nimir AR, Saliem A, Ibrahim IA. Ophthalmic parasitosis: a review article. *Interdiscip Perspect Infect Dis*. 2012; 2012(September):587402–10. 2012
- 2 Bradbury RS, Gustafson DT, Sapp SGH, Fox M, De Almeida M, Boyce M, et al. A second case of human conjunctival infestation with thelazia gulosa and a review of T. gulosa in North America. *Clin Infect Dis*. 2020;70(3):518–20.
- 3 Yang YJ, Liag TH, Lin SH, Chen HC, Lai SC. Human thelaziasis occurrence in Taiwan. *Clin Exp Optom*. 2006;89(1):40–4.
- 4 Chanie M, Bogale B. Thelaziasis: biology, species affected and pathology (Conjunctivitis): a review. *Acta Parasitol Glob*. 2014;5(1):65–8.
- 5 Otranto D, Cantacessi C, Testini G, Lia RP. Phortica variegata as an intermediate host of Thelazia callipaeda under natural conditions: evidence for pathogen transmission by a male arthropod vector. *Int J Parasitol*. 2006 Sep;36(10–11):1167–73.
- 6 Otranto D, Dutto M. Human Thelaziasis, Europe. *Emerg Infect Dis*. 2008;14(4):647–9.
- 7 Sah R, Khadka S, Adhikari M, Niraula R, Shah A, Khatri A, et al. Human thelaziasis: emerging ocular pathogen in Nepal. *Open Forum Infect Dis*. 2018;5(10):ofy237.
- 8 Liu SN, Xu FF, Chen WQ, Jiang P, Cui J, Wang ZQ, et al. A case of human Thelaziasis and review of Chinese cases. *Acta Parasitol*. 2020;65(3):783–6.
- 9 Sohn WM, Na BK, Yoo JM. Two cases of human thelaziasis and brief review of Korean cases. *Korean J Parasitol*. 2011;49(3):265–71.
- 10 Do Vale B, Lopes AP, Da Conceição Fontes M, Silvestre M, Cardoso L, Coelho AC. Systematic review on infection and disease caused by Thelazia callipaeda in Europe: 2001–2020. *Parasite*. 2020;27:52.

- 11 Viriyavejakul P, Krudsood S, Monkhonmu S, Punsawad C, Riganti M, Radomyos P. Thelazia callipaeda: a human case report. *Southeast Asian J Trop Med Public Health*. 2012 Jul;43(4):851–6.
- 12 Nguyen VD, Thanh HL, Chai JY. The first human case of thelazia callipaeda infection in Vietnam. *Korean J Parasitol*. 2012 Aug;50(3):221–3.
- 13 Agha RA, Borrelli MR, Farwana R, Koshy K, Fowler AJ, Orgill DP, et al. The SCARE 2018 statement: updating consensus Surgical CAse REport (SCARE) guidelines. *Int J Surg*. 2018;60(October):132–6.
- 14 Singh K, Khindria A. First case of human ocular Thelaziasis from India caused by Thelazia californiensis: a case report. *J Dent Med Sci*. 2018;17(01):24–7.
- 15 Kosin E, Kosman ML, Depary AA. First case of human Thelaziasis in Indonesia. *Southeast Asian J Trop Med Public Health*. 1989 Jun;20(2):233–6.
- 16 Purnima B, Parveez U, Angshurekha D, Uttara B. Thelaziasis: an emerging ocular parasite in Northeast of India. *Int J Heal Res Med Leg Pract*. 2019;5(1):20.
- 17 Otranto D, Lia RP, Buono V, Traversa D, Giangaspero A. Biology of Thelazia callipaeda (spirurida, thelaziidae) eyeworms in naturally infected definitive hosts. *Parasitology*. 2004;129(5):627–33.
- 18 Rolbiecki L, Izdebska JN, Franke M, Iлизко L, Fryderyk S. The vector-borne zoonotic nematode thelazia callipaeda in the eastern part of Europe, with a clinical case report in a dog in Poland. *Pathogens*. 2021;10(1):1–7.
- 19 Prasertsilpa S, Bhaibulaya M, Vajrasthira S. Thelazia Callipaeda (Railliet and Henry, 1910) in man and dog in Thailand. *Am J Trop Med Hyg*. 1970 May;19(3):476–9.
- 20 Eser M, Miman Ö, Acar A. Thelazia callipaeda (Railliet and Henry, 1910) case in a dog: First record in Turkey. *Kafkas Univ Vet Fak Derg*. 2019;25(1):129–32.
- 21 Pal A, Atreya A, Maharjan N, Mahat M, Bom R. Human ocular Thelaziasis: a case report. *J Nepal Med Assoc*. 2021;59(242):1060–2.
- 22 Luo B, Xiang N, Liu R, Wang W, Li Y, Qi X. Phthiriasis palpebrarum, thelaziasis, and ophthalmomyiasis. *Int J Infect Dis*. 2020;96:511–6.
- 23 Otranto D, Dantas-Torres F. Transmission of the eyeworm Thelazia callipaeda: between fantasy and reality. *Parasit Vectors*. 2015;8(1):273–9.
- 24 Krishnachary PS, Shankarappa VG, Rajarathnam R, Shanthappa M. Human ocular thelaziasis in Karnataka. *Indian J Ophthalmol*. 2014;62(7):822–4.
- 25 Chai JY, Jung BK, Hong SJ. Albendazole and mebendazole as anti-parasitic and anti-cancer agents: an update. *Korean J Parasitol*. 2021;59(3):189–225.
- 26 Naem S. Thelazia species and conjunctivitis. In: Pelikan Z, editor. *A complex and multifaceted disorder*. InTech; 2011. p. 201–20.

# Human Ocular Thelaziasis: A Case Report from Indonesia

## ORIGINALITY REPORT

22%

SIMILARITY INDEX

18%

INTERNET SOURCES

19%

PUBLICATIONS

8%

STUDENT PAPERS

## PRIMARY SOURCES

1	<a href="http://www.jnma.com.np">www.jnma.com.np</a> Internet Source	2%
2	<a href="http://academic.oup.com">academic.oup.com</a> Internet Source	1%
3	<a href="http://downloads.hindawi.com">downloads.hindawi.com</a> Internet Source	1%
4	<a href="http://link.springer.com">link.springer.com</a> Internet Source	1%
5	<a href="http://coek.info">coek.info</a> Internet Source	1%
6	<a href="http://pure.rug.nl">pure.rug.nl</a> Internet Source	1%
7	Aaron G. Issac, David Szafron, Dongguang Wei, Jennifer L. McQuade, Yinghong Wang. "Severe Inflammatory Colitis Related to Encorafenib and Binimetinib following Immune Checkpoint Inhibitor Therapy", Case Reports in Gastroenterology, 2022 Publication	1%

8	<a href="http://boris.unibe.ch">boris.unibe.ch</a> Internet Source	1 %
9	<a href="http://www.cdc.gov">www.cdc.gov</a> Internet Source	1 %
10	<a href="http://d.researchbib.com">d.researchbib.com</a> Internet Source	1 %
11	Lima, Alexandre, Michel E van Genderen, Jasper van Bommel, Eva Klijn, Tim Jansem, and Jan Bakker. "Nitroglycerin reverts clinical manifestations of poor peripheral perfusion in patients with circulatory shock", <i>Critical Care</i> , 2014. Publication	1 %
12	Parinya Wilai, Rusdiah Sudirman Made Ali, Jassada Saingamsook, Atiporn Saeung et al. "Integrated systematics of <i>Anopheles subpictus</i> (Diptera: Culicidae) in the Oriental Region, with emphasis on forms in Thailand and Sulawesi, Indonesia", <i>Acta Tropica</i> , 2020 Publication	1 %
13	<a href="http://discovery.researcher.life">discovery.researcher.life</a> Internet Source	1 %
14	<a href="http://www.Karger.com">www.Karger.com</a> Internet Source	1 %
15	<a href="http://mts.intechopen.com">mts.intechopen.com</a> Internet Source	1 %

16	<a href="http://www.hindawi.com">www.hindawi.com</a> Internet Source	1 %
17	Submitted to Universitas Airlangga Student Paper	1 %
18	Submitted to Mansoura University Student Paper	<1 %
19	P. Oyarzún-Ruiz, P. Muñoz-Alvarado, E. Raffo. "Helminths of <i>Milvago chimango temucoensis</i> (Aves: Falconiformes) from Los Ríos Region, Chile: New Records for Neotropical Raptors", <i>Helminthologia</i> , 2016 Publication	<1 %
20	<a href="http://balimedicaljournal.org">balimedicaljournal.org</a> Internet Source	<1 %
21	<a href="http://journal.kisep.com">journal.kisep.com</a> Internet Source	<1 %
22	<a href="http://www.pubmedcentral.nih.gov">www.pubmedcentral.nih.gov</a> Internet Source	<1 %
23	Guo-Hua Liu, Robin B. Gasser, Domenico Otranto, Min-Jun Xu, Ji-Long Shen, Namitha Mohandas, Dong-Hui Zhou, Xing-Quan Zhu. "Mitochondrial Genome of the Eyeworm, <i>Thelazia callipaeda</i> (Nematoda: Spirurida), as the First Representative from the Family Thelaziidae", <i>PLoS Neglected Tropical Diseases</i> , 2013	<1 %

24 [idoc.pub](http://idoc.pub) Internet Source <1 %

---

25 [iopscience.iop.org](http://iopscience.iop.org) Internet Source <1 %

---

26 [pubmed.ncbi.nlm.nih.gov](http://pubmed.ncbi.nlm.nih.gov) Internet Source <1 %

---

27 Rizzo, Vincenzo, Carmen Terranova, Alfredo Conti, Antonino Germanò, Concetta Alafaci, Giovanni Raffa, Paolo Girlanda, Francesco Tomasello, and Angelo Quartarone. "Preoperative functional mapping for rolandic brain tumor surgery", Neuroscience Letters, 2014. Publication <1 %

---

28 Sudha Shahi, Anuj Devkota, Tika Ram Bhandari, Tridip Pantha, Dipendra Gautam. "Rare giant maxillary mucocele: A rare case report and literature review", Annals of Medicine and Surgery, 2019. Publication <1 %

---

29 [assets.researchsquare.com](http://assets.researchsquare.com) Internet Source <1 %

---

30 [www.ijo.in](http://www.ijo.in) Internet Source <1 %

---

31

Baruš, V., T. P. Sergeeva, M. D. Sonin, K. M. Ryzhikov, and B. Ryšavý. "Systematic Part", Helminths of Fish-Eating Birds of the Palaeartic Region, 1978.

Publication

<1 %

32

Riaz A. Agha, Mimi R. Borrelli, Reem Farwana, Kiron Koshy et al. "The SCARE 2018 statement: Updating consensus Surgical CAse REport (SCARE) guidelines", International Journal of Surgery, 2018

Publication

<1 %

33

Ranjit Sah, Shusila Khadka, Mahesh Adhikari, Reema Niraula, Apoorva Shah, Anadi KC, Suzanne Donovan. "Human Thelaziasis: Emerging Ocular Pathogen in Nepal", Open Forum Infectious Diseases, 2018

Publication

<1 %

Exclude quotes  On

Exclude bibliography  On

Exclude matches  < 5 words